

Organization of the Body

Chapter 1

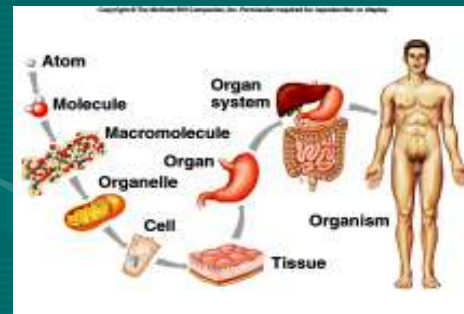The Human Body

- A. Anatomy & physiology is the study of the human body.
1. **Anatomy**: concerned with the structure of a part
 2. **Physiology**: concerned with the function of a part

- B. Anatomy & physiology are closely connected in that the structure of an organ suits its function.

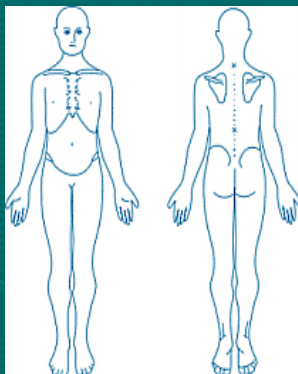
1. Stomach is pouchlike & able to expand=perfect for storing food.
2. Fingers are long, jointed=perfect for grasping things.

- C. The structure of the body can be studied at different levels of organization ranging from atoms to the organism.



- D. Various terms are used to describe the location of body parts when the body is in the anatomical position.

1. **Anatomical position**: standing erect, with face forward, arms at the sides, and palms and toes directed forward.



Directional Terms

2. **Directional terms** describe the location of one body part in relation to another.

Anterior	Posterior
Superior	Inferior
Medial	Lateral
Proximal	Distal
Superficial	Deep
Ventral	Dorsal


- **Anterior**
- **Posterior**

A body part is toward the front.

A body part is toward the back.

The eyes are anterior to the brain.

The brain is posterior to the eyes.



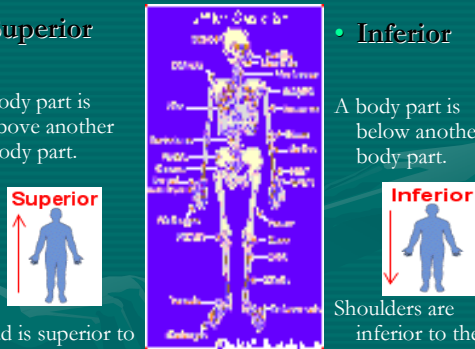
- **Superior**
- **Inferior**

A body part is above another body part.

A body part is below another body part.

Head is superior to shoulders...

Shoulders are inferior to the head...



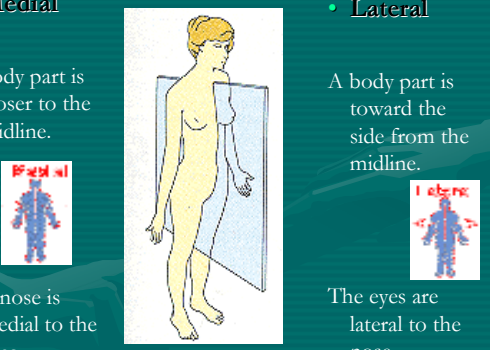
- **Medial**
- **Lateral**

A body part is closer to the midline.

A body part is toward the side from the midline.

The nose is medial to the eyes.

The eyes are lateral to the nose.



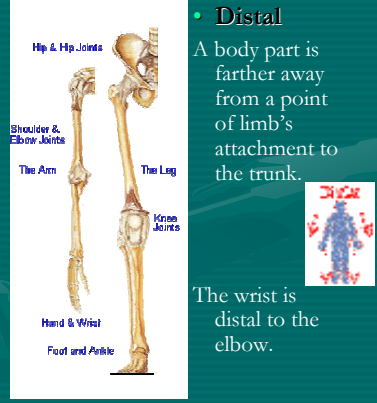
- **Proximal**
- **Distal**

A body part is closer to a point of limb's attachment to the trunk.

A body part is farther away from a point of limb's attachment to the trunk.

The elbow is proximal to the wrist.

The wrist is distal to the elbow.



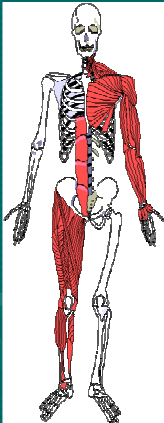
- **Superficial**
- **Deep**

The body part is situated near the surface.

The body part is internal, beneath the surface.

The skin is superficial to the muscles.

The muscles are deep to the skin.



- **Ventral**
- **Dorsal**

A body is toward the belly surface of the body.

A body part is toward the vertebral surface of the body.

Stomach is ventral to the spine.

Spine is dorsal to the stomach.

